


Takotsubo Cardiomyopathy in a Post-Menopausal Female Patient with Traumatic Brain Injury: A Case Report

Gilbert Siu, DO, PhD¹, Rohini Kumar, MD¹, and Thomas Watanabe, MD²

¹Department of Physical Medicine & Rehabilitation, Temple University Hospital, Philadelphia, PA

²MossRehab, Elkins Park, PA



ABSTRACT

Neurological deficits and medical complications are common sequelae after traumatic brain injury (TBI). Among the medical complications, cardiomyopathies are relatively rare. We describe a case of a 65-year-old post-menopausal female with past medical history of hypertension, hypothyroidism, and hyperlipidemia, who fell and struck her head on the basement wall, and presented with confusion and right-sided weakness. Head computed tomography revealed an acute left subdural hematoma with midline shift. The patient underwent emergent left craniectomy with evacuation. During her hospital course, the patient developed chest pain and dyspnea. The electrocardiogram showed sinus tachycardia with ST elevations at the precordial leads, while the echocardiogram showed left ventricular hypokinesis around the apical region. In addition, the patient's cardiac enzymes were mildly elevated, presenting as an acute coronary syndrome. However, once the patient underwent coronary angiography, the angiogram demonstrated the absence of obstructive coronary disease or acute plaque rupture. The patient was diagnosed with Takotsubo cardiomyopathy (TC), a relatively recently identified cause of cardiac dysfunction. It is an acute, stress-induced form of reversible heart failure, characterized by transient left ventricular apical ballooning with akinesia. With appropriate cardiac interventions and precautions, the patient progressed functionally in the inpatient rehabilitation to an independent level and was discharged home. TC occurs predominantly in post-menopausal females after an emotional or physical stress exposure. Elevated levels in catecholamines from the stress exposure, which can be seen after a TBI, have been suggested to play a role in the pathogenesis of TC. This cardiomyopathy mimics acute myocardial infarction without the presence of coronary stenosis or ruptured plaque on coronary angiogram; differences in treatment are discussed. This case highlights known risk factors, including the possibility that this complication may be seen after TBI, and therefore clinicians should be aware of this cause of cardiomyopathy.

CASE DESCRIPTION

A 65-year-old post-menopausal female with past medical history of hypertension, hypothyroidism, and hyperlipidemia, who fell downstairs and struck her head on the basement wall, presented with confusion and right-sided weakness. **Imaging:** Head computed tomography revealed an acute left frontoparietal subdural hematoma with rightward midline shift. The patient underwent emergent left craniectomy with evacuation. A few days after surgery, the patient developed chest pain and dyspnea. **Cardiac Studies:** Electrocardiogram showed sinus tachycardia at a rate of 110 beats per minute with ST elevations at the precordial leads. The transthoracic echocardiogram showed left ventricular hypokinesis around the apical region. **Laboratory studies:** Cardiac enzymes were mildly elevated. The patient was diagnosed with acute coronary syndrome. Emergent coronary angiography was performed and demonstrated the absence of obstructive coronary disease or acute plaque rupture. **Diagnosis:** The initial diagnosis was acute coronary syndrome, but instead the patient had Takotsubo cardiomyopathy. **Rehabilitation and Treatment:** The patient was subsequently transferred to acute inpatient rehabilitation. Medications including aspirin, metoprolol, furosemide and lisinopril were used to treat TC along with cardiac precautions (holding therapy if systolic blood pressure was greater than 160 or heart rate greater than 110) during the patient's rehabilitation. She made remarkable improvement in ambulation, cognition and function after the brain injury rehabilitation and was discharged home at an independent level.

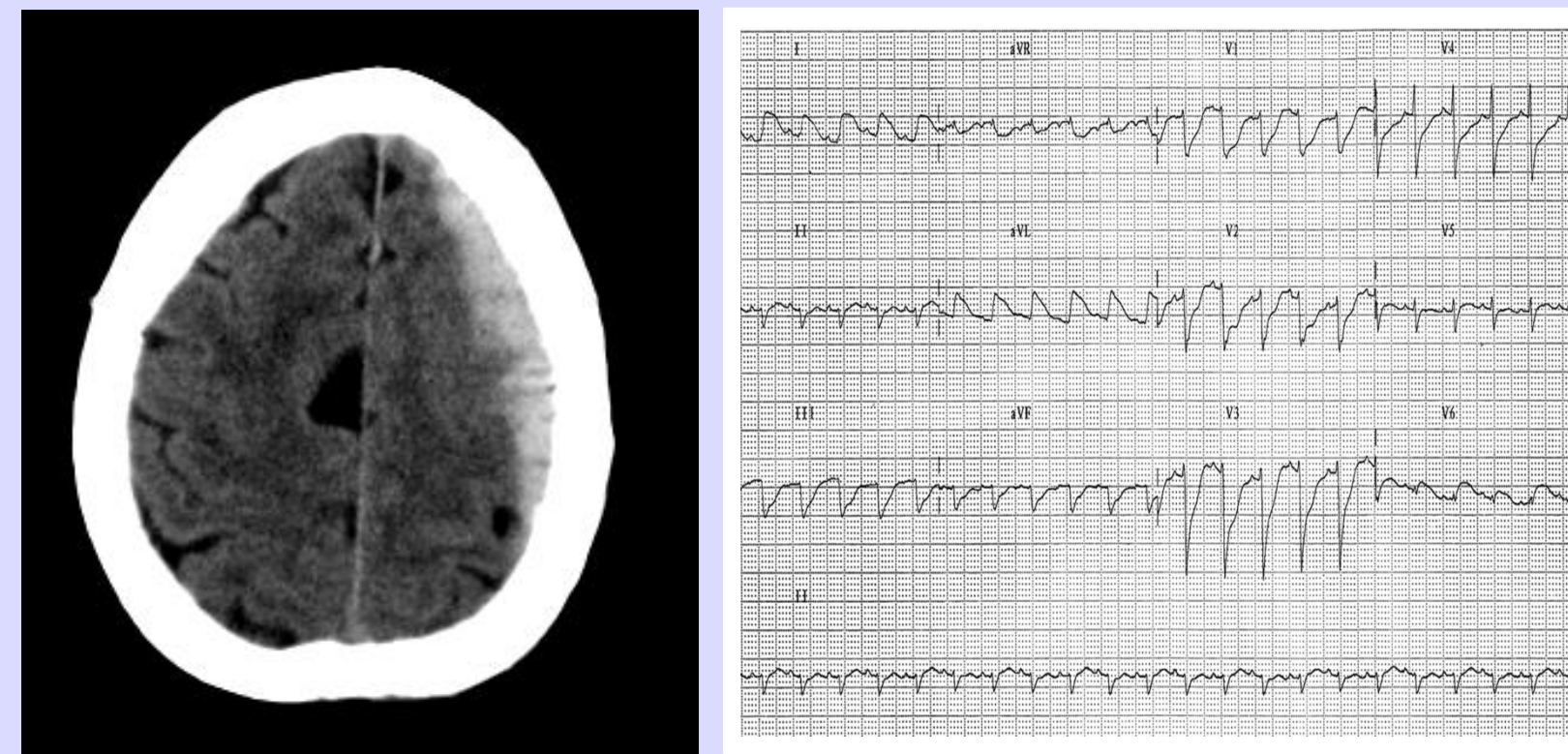


Figure 1. (A) Computed tomography of the brain reveals a left frontoparietal subdural hematoma covering the left lateral convexity with midline shift. (B) Electrocardiogram demonstrating sinus tachycardia with ST elevations.

Takotsubo Cardiomyopathy	Acute Coronary Syndrome
Alleviate physical and emotional stress	Thrombolytics
Treatment similar to heart failure due to left ventricular systolic dysfunction:	Beta-blockers, Aspirin, ACE inhibitor or ARB, Nitroglycerin
Beta-blocker, ACE inhibitor or ARB, Diuretic, Aspirin	Angioplasty and stenting Coronary bypass surgery

Table 1. Treatment of Takotsubo cardiomyopathy versus acute coronary syndrome.

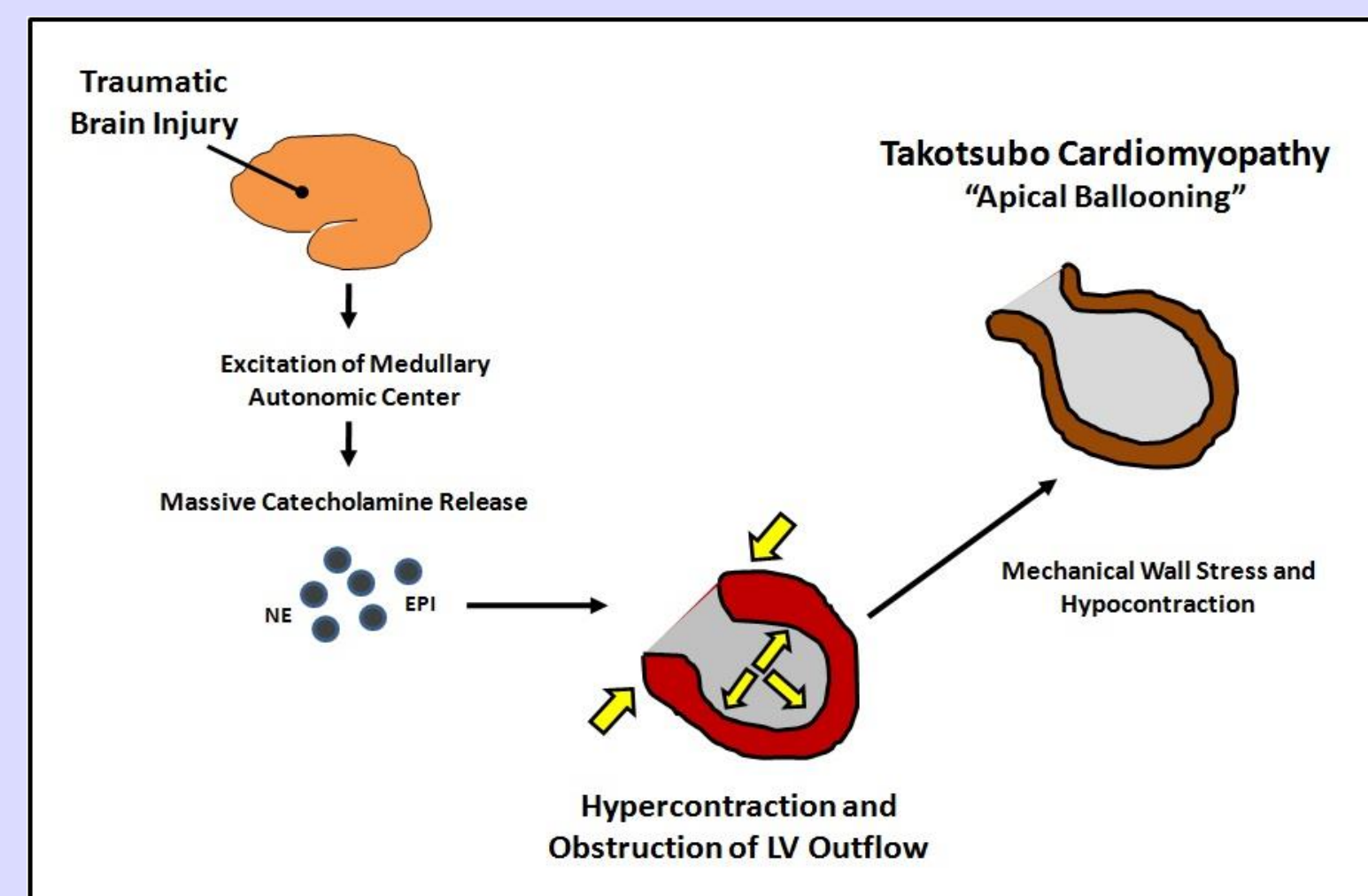


Figure 2. Proposed mechanism of traumatic brain injury leading to takotsubo cardiomyopathy

DISCUSSION

Takotsubo cardiomyopathy (TC) occurring in neurocritically ill patients is also known as stress-induced cardiomyopathy, catecholaminergic cardiotoxicity, or neurogenic myocardial stunning. It is a unique reversible form of cardiac dysfunction with an intricate pathophysiology. Following a severe intracranial process, there is a surge of catecholamines leading to a cardiotoxic state, resulting in a non-coronary distribution of wall motion abnormalities. Patients with TC have mildly elevated levels of cardiac biomarkers, while the serum catecholamine levels are 2-to 3- fold higher when compared to a patient presenting with an acute myocardial infarction (MI). The catecholamine-mediated mechanism leads to the dysregulation of the cardiovascular, autonomic, endocrine and central nervous systems. Differ from MI, the coronary angiography will show the absence of obstructive coronary disease or acute plaque rupture. 70-80% of TC cases are reported in postmenopausal women aged 60-75 years. Postmenopausal women are predisposed to TC and more vulnerable to stress induced events as estrogen serves as a cardioprotective agent. With respect to treatment, patients are considered to be treated as left ventricular systolic dysfunction and management will include: supportive care, aspirin, beta blockers, angiotensin-converting-enzyme inhibitors, statins, cardiac catheterization and diuretics as needed. Due to the compromised left ventricular (LV) function, TC patients should be on anticoagulation to prevent LV thrombus formation and have follow-up surveillance echocardiographies. The cardiac status during the acute phase of TC equates to New York Heart Association class III heart failure, thus patients undergoing rehabilitation must have strict cardiac precautions. Despite the reversibility of the disease process, patients are still at risk for progression of symptoms including cardiogenic shock, heart failure, ventricular rupture, catecholamine-mediated arrhythmias and pulmonary edema. In 95% of cases, TC is a self- limited entity and left ventricular function does improve within 1-3 months. It is critical for physiatrists to be aware of TC and recognize it in the TBI patient population, particularly post-menopausal females. The course of rehabilitation will be a fusion of cardiopulmonary and TBI therapies.

CONCLUSION

We present an uncommon complication of a traumatic brain injury which presents similarly to acute myocardial infarction but without the presence of coronary stenosis or ruptured plaque on coronary angiogram. It is important that clinicians recognize the known risk factors, diagnostic studies, distinct signs and symptoms of Takotsubo cardiomyopathy in order to permit early and proper diagnosis, pharmacologic intervention, and rehabilitation.

REFERENCES

1. Akashi YJ, Goldstein DS, Barbaro G, Ueyama T. Takotsubo cardiomyopathy: a new form of acute, reversible heart failure. *Circulation* 2008;118(25):2754-62.
2. Bybee KA and Prasad A. Stress-Related Cardiomyopathy Syndromes. *Circulation* 2008;118:397-409
3. de Gregorio C, Ando G, Lentini C, Carerj S. Transient left ventricular dysfunction and stroke: An intriguing mystery still far from being fully elucidated. *Int J Cardiol* 2009.
4. Metzli MD, Altman EJ, Spevack DM, Doddamani S, Travin MI, Ostfeld RJ. A case of Takotsubo cardiomyopathy mimicking an acute coronary syndrome. *Nat Clin Pract Cardiovasc Med* 2006;3(1):53-6; quiz 7.
5. Riera M, Llompert-Pou JA, Carrillo A, Blanco C. Head injury and inverted Takotsubo cardiomyopathy. *J Trauma*;68(1):E13-5.
6. Yoshimura S, Toyoda K, Ohara T, Nagasawa H, Ohtani N, Kuwashiro T et al. Takotsubo cardiomyopathy in acute ischemic stroke. *Ann Neurol* 2008;64(5):547-54.